


**PATIENT**

Abby Dejong

**SPECIES**

Canine

**BREED**

Golden Retriever

**SEX**

Female Spayed

**AGE**

9.5 years

**PRESENTING CLINICAL SIGNS**

History: History of hypothyroidism. Has had off and on GI issues with abdominal fullness and discomfort. Is on Thyrotabs but in the AM only. No heart murmur noted. Seen for increased lethargy, acting very tired and new vision loss(bumping into things.). Suspected possible focal mass in mid abdomen on radiographs and intervertebral heart score greater than 3. Most recently noticed sudden weight gain, hypertension and consistent elevated BP ranging from 180-200/100.

**ECHOCARDIOGRAM FINDINGS**

2D, m-mode, color flow and doppler imaging is available. Normal mitral valve leaflets with no prolapse into the left atrial lumen. Trace mitral regurgitation with normal left atrial dimension. Normal LV diameter with adequate myocardial function. The tricuspid valve appears normal with no tricuspid regurgitation. Normal right atrial and ventricular diameter and morphology indicating no overt evidence of pulmonary arterial hypertension. The pulmonic and aortic valves are normal in morphology and mobility. Normal pulmonic and aortic outflow velocities with laminar flow. No obvious aortic or pulmonic insufficiency. No pericardial or pleural effusion noted. No obvious cardiac masses.

**CARDIAC CHART**
**WEIGHT**

75lbs

**INTERPRETED BY**

 Maggie Machen Lamy,  
 DVM DACVIM  
 (Cardiology)

**IMAGING PERFORMED BY**

Crystal Hill, RVT

**HOSPITAL NAME**

 Grand River  
 Veterinary Hospital

**REFERRING VET**

Dr. Hornak

CANINE CARDIAC PARAMETERS	MR VMAX (m/s)	TR VMAX (m/s)	LA/AO (Boon method)	LA/AO (Heart Base; Swe)	FS (%)	EF (%)	EPSS (cm)
NORMAL PARAMETER	4.5-5.5	<2.7	1.3	<1.6	28-40	40-100	<0.6
PATIENT	NM	NA	1.0	1.0	30	58	0.5
CANINE CARDIAC PARAMETERS	HR (BPM)	AV VMAX (m/s)	PV MAX (m/s)	BODY WEIGHT (kg)	LA 2D short axis Base view (cm)	LVIDd Avg; 2D and m-mode short axis (cm)	LVIDs Avg; 2D and m-mode short axis (cm)
NORMAL PARAMETER	50-100	0.7-1.7	0.7-1.6	BELOW	BELOW	BELOW	BELOW
PATIENT	NM	1.5	1.3	34.0	2.0	4.3	3.0
*Normal chamber parameters expressed as a mean value (SD)				3	1.27 (5.3)	2.46 (2.46)	1.36 (5.5)
<b>BODY WEIGHT DEPENDENT PARAMETERS</b>				5	1.40 (4.5)	2.74 (5.2)	1.60 (4.7)
*Note: All measurements based upon multi-modal images and methods. An average value is reported.				10	1.50 (3.8)	3.27 (3.5)	2.06 (3.1)
				15	1.83 (2.0)	3.71 (2.4)	2.43 (2.1)
				20	2.02 (1.9)	4.14 (2.2)	2.80 (2.0)
				25	2.18 (2.4)	4.48 (2.9)	3.10 (2.5)
				30	2.33 (3.3)	4.83 (3.9)	3.39 (3.4)
				35	2.48 (4.3)	5.17 (5.0)	3.69 (4.5)
				40	2.62 (5.2)	5.48 (6.1)	3.96 (5.4)
				50	2.88 (7.1)	6.07 (8.3)	4.46 (7.4)

**INTERPRETATION OF THE FINDINGS & FURTHER RECOMMENDATIONS**

Overtly normal cardiac dimensions and function, with no obvious dysfunction or dilation of the left heart. No significant valvular leaks are visualized, and no evidence of pulmonary hypertension.

**INVOICE**

24592

**DATE**

6/6/22



**PATIENT**

Abby Dejong

No evidence of pathologic/chronic systemic hypertension is seen in this study. Consider reassess the values prior to proceeding. If deemed accurate, treatment is certainly warranted. Screening for underlying causes, such as an adrenal tumor is recommended.

**SPECIES**

Canine

Monitor for development of a heart murmur, cough, labored breathing, exercise intolerance or collapse episodes.

**BREED**

Golden Retriever

A recheck echocardiogram is recommended should a significant murmur develop, or signs of cardiac compromise be noted in the future.

**IMAGES**

**SEX**

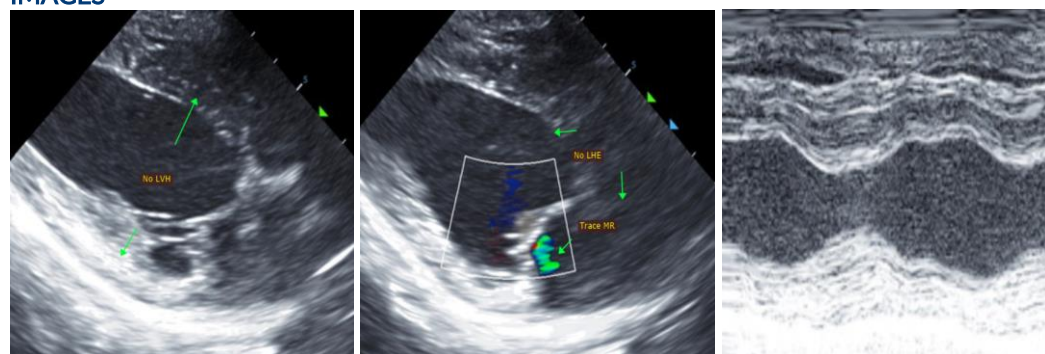
Female Spayed

**AGE**

9.5 years

**WEIGHT**

75lbs



**INTERPRETED BY**

Maggie Machen Lamy,  
DVM DACVIM  
(Cardiology)

The information and recommendations provided are based on the images presented by the referring veterinarian. No evaluation can be communicated regarding pathology that was not visible in the image/video clips provided.

Thank you for this referral. This report was generated using transcription software, and minor dictation errors may be present. If the clinical or image interpretation does not parallel your findings or if I can be of any further assistance, please contact me.

**IMAGING PERFORMED BY**

Crystal Hill, RVT

Maggie Machen Lamy, DVM  
Diplomate of the American College of Veterinary Internal Medicine (Cardiology)  
info@sonopath.com

**HOSPITAL NAME**

Grand River  
Veterinary Hospital

**REFERRING VET**

Dr. Hornak

**INVOICE**

24592

**DATE**

6/6/22